

## Original Studies

# Expert Consensus Statement on the Use of Fractional Flow Reserve, Intravascular Ultrasound, and Optical Coherence Tomography: A Consensus Statement of the Society of Cardiovascular Angiography and Interventions

Amir Lotfi,<sup>1</sup> MD, FSCAI, Allen Jeremias,<sup>2</sup> MD, FSCAI, William F. Fearon,<sup>3</sup> MD, FSCAI, Marc D. Feldman,<sup>4</sup> MD, FSCAI, Roxana Mehran,<sup>5</sup> MD, John C. Messenger,<sup>6</sup> MD, FSCAI, Cindy L. Grines,<sup>7</sup> MD, FSCAI, Larry S. Dean,<sup>8</sup> MD, FSCAI, Morton J. Kern,<sup>9</sup> MD, FSCAI, and Lloyd W. Klein,<sup>10\*</sup> MD, FSCAI

**Key words:** fractional flow reserve; imaging; intravascular ultrasound; imaging; optical coherence tomography; interventional devices/innovation

## INTRODUCTION

The rationale for use of intracoronary physiology assessment and imaging arises from the limitations of coronary angiography, the traditional method for determining the severity of coronary stenoses. The visual assessment of percent diameter reduction has significant interobserver variability [1–3], even among experienced angiographers [4]. Computer-assisted quantitative coronary angiography only marginally improves diagnostic accuracy and its estimate of functional significance [5].

Fractional flow reserve (FFR) is used to determine the functional significance of a coronary stenosis [6]. Intravascular ultrasound (IVUS) offers excellent visualization of intraluminal and transmural coronary anatomy. Optical coherence tomography (OCT) further improves vascular visualization. There is now persuasive evidence regarding intracoronary diagnostic lesion assessments using physiology and anatomy. These adjunctive diagnostic procedures may influence the decision for coronary revascularization, guide the performance of percutaneous coronary interventions (PCI), and optimize procedural outcomes. There are substantial long-term outcome data showing benefit associated with FFR-guided decision-making. However, these techniques are underutilized in contemporary practice: the rates of use of IVUS and FFR during PCI for intermediate coronary stenoses (40–70% diameter stenosis) are 20.3% and 6.1% respectively [7].

In 2011, the ACCF/AHA/SCAI PCI guidelines [8] assigned levels of evidence for the use of these modalities in various clinical situations (Table I). The purpose of this consensus statement is to review recent studies, to develop a consensus of how these

T1

<sup>1</sup>Baystate Medical Center, Springfield, Massachusetts

<sup>2</sup>Stony Brook University Medical Center, Stony Brook, New York

<sup>3</sup>Stanford University Medical Center, Stanford, California

<sup>4</sup>University of Texas Health Science Center in San Antonio, San Antonio, Texas

<sup>5</sup>Mount Sinai School of Medicine, New York, New York

<sup>6</sup>University of Colorado School of Medicine, Aurora, Colorado

<sup>7</sup>Detroit Medical Center, Detroit, Michigan

<sup>8</sup>University of Washington School of Medicine, Seattle, Washington

<sup>9</sup>Long Beach Veterans Administration Hospital; University of California, Irvine, California

<sup>10</sup>Advocate Illinois Masonic Medical Center; Rush Medical College, Chicago, Illinois

Conflict of interest: Nothing to report.

\*Correspondence to: Lloyd W. Klein, MD, FSCAI, Professional Office Building Suite 625, 3000 North Halsted, Chicago, IL 60614. E-mail: lloydklein@comcast.net

Received 27 September 2013; Revision accepted 29 September 2013

DOI: 10.1002/ccd.25222

Published online 00 Month 2013 in Wiley Online Library (wileyonlinelibrary.com)

2 Lotfi et al.

TABLE I. 2011 PCI Guideline Recommendations [8]

5.4.1 FFR: Recommendation

CLASS IIa

1. FFR is reasonable to assess angiographic intermediate coronary lesions (50% to 70% diameter stenosis) and can be useful for guiding revascularization decisions in patients with SIHD. (Level of Evidence: A)

5.4.2 IVUS: Recommendations

CLASS IIa

1. IVUS is reasonable for the assessment of angiographically indeterminate left main CAD. (Level of Evidence: B)
2. IVUS and coronary angiography are reasonable 4 to 6 weeks and 1 year after cardiac transplantation to exclude donor CAD, detect rapidly progressive cardiac allograft vasculopathy, and provide prognostic information. (Level of Evidence: B)
3. IVUS is reasonable to determine the mechanism of stent restenosis. (Level of Evidence: C)

CLASS IIb

1. IVUS may be reasonable for the assessment of non-left main coronary arteries with angiographically intermediate coronary stenosis (50% to 70% diameter stenosis). (Level of Evidence: C)
2. IVUS may be considered for guidance of coronary stent implantation, particularly in cases of left main coronary artery stenting. (Level of Evidence: B)
3. IVUS may be reasonable to determine the mechanism of stent thrombosis. (Level of Evidence: C)

CLASS III: NO BENEFIT

1. IVUS for routine lesion assessment is not recommended when revascularization with PCI or CABG is not being contemplated. (Level of Evidence: C)

5.4.3 Optical Coherence Tomography

The appropriate role for optical coherence tomography in routine clinical-decision making has not been established.

procedures are best utilized in practice, and to support their incorporation into guideline and appropriate use documents.

Fractional Flow Reserve (FFR)

A trans-lesional functional assessment is an important adjunct to coronary angiography for providing an objective evaluation of stenosis severity. FFR is the ratio of mean distal coronary pressure (Pd) to mean aortic pressure (Pa) during maximum hyperemia, usually induced by adenosine i.c. bolus or i.v. infusion, and represents the percentage of normal flow across a coronary stenosis. If the patient has active obstructive airways disease, i.c. adenosine can be used safely instead of IV adenosine. Alternative pharmacologic agents include nitroprusside, dobutamine, and regadenoson.

Physiologic stenosis assessment by FFR is a lesion-specific index of epicardial conductance, which is independent of the microvasculature and hemodynamic changes induced by variations in heart rate, blood pressure or myocardial contractility. The FFR threshold for detecting ischemia has been corroborated by multiple tests for myocardial ischemia and reflects the func-

Catheterization and Cardiovascular Interventions DOI 10.1002/ccd.

Published on behalf of The Society for Cardiovascular Angiography and Interventions (SCAI).

Discordance between nuclear perfusion scan result and FFR in 67 patients with angiographic 2 or 3 vessel CAD

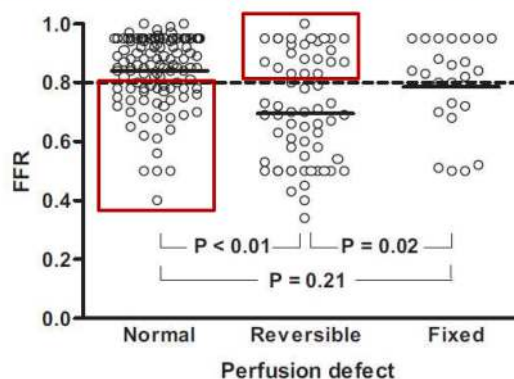


Fig. 1. Discordance between nuclear perfusion scan result and FFR in 67 patients with angiographic two- or three-vessel CAD. Adapted from Melikian et al., J Am Coll Cardiol Interv, 2010, 3, 307-314 [10], ©Elsevier; and from Tonino et al., N Engl J Med, 2009, 360, 213-224 [12], ©Massachusetts Medical Society.

tional significance (i.e. ischemic potential) of an epicardial stenosis. To establish an ischemic threshold, FFR was validated in patients with single vessel intermediate lesions and compared with the combination of three different noninvasive stress tests [9]. FFR was first validated using a cutoff value of 0.75. With further experience with the technique, investigators appreciated that by extending the cutoff value to 0.80, the sensitivity of FFR could be improved without greatly compromising the specificity. For this reason, a cutoff value of ≤0.80 was used in FAME 1 and FAME 2 and shown to be clinically valid. This is now the recommended ischemic reference standard for the invasive assessment of myocardial ischemia [10] (Fig. 1).

Correlation with Clinical Outcomes

Three prospective randomized trials have demonstrated the clinical utility of FFR. To determine the safety of deferring PCI based on nonsignificant FFR, the Percutaneous Coronary Intervention of Functionally Non-significant Stenosis (DEFER) Study [12] randomized 181 patients with stable ischemic heart disease (SIHD) with FFR ≥0.75 across an intermediate stenosis to PCI or to deferral of PCI with medical treatment. At 5-year follow-up, the deferred group had a rate of death or myocardial infarction (MI) that was less than half the rate in the PCI group.

To evaluate the utility of FFR for guiding the performance of PCI, the Fractional Flow Reserve versus Angiography for Multivessel Evaluation (FAME) trial [12] randomized 1005 patients with multivessel disease (including SIHD, unstable angina, and NSTEMI) to

COLOR

F1

### FAME Trial: One Year Outcomes

COLOR

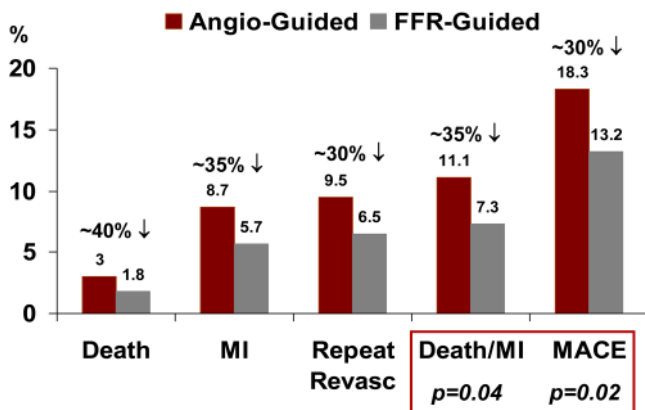


Fig. 2. FAME trial: 1-year outcomes. Adapted from Tonino et al., N Engl J Med, 2009, 360, 213-224 [12], ©Massachusetts Medical Society.

either FFR-guided PCI or to angiography-guided PCI. The primary outcome, the composite rate of death, MI, or repeat revascularization at 1 year, was significantly lower (13.2% vs. 18.3%,  $P=0.02$ ) in patients who received FFR-guided PCI (Fig. 2). This was due to non-significant reductions in each component of the primary endpoint and a significant reduction in the combined rate of death or MI (7.3% vs. 11.1%,  $P=0.04$ ) in the FFR-guided group. At 2-year follow-up, the combined rate of death and MI remained significantly lower. An economic evaluation verified that FFR-guided PCI is a cost-saving strategy [13], with significantly fewer stents deployed and significantly less contrast media used. Additionally, patients treated with the FFR-guided strategy had similar rates of freedom from angina compared with the angiography-guided strategy.

To compare outcomes in ischemia-guided PCI with medical therapy, the Fractional Flow Reserve versus Angiography for Multivessel Evaluation 2 (FAME 2) trial [14] randomized 888 patients with single or multivessel SIHD to FFR-guided PCI with optimal medical therapy or optimal medical therapy alone. The key difference between FAME 2 and other studies evaluating PCI for SIHD, such as COURAGE [15], is that to be included in the randomized portion of FAME 2, patients had to have at least one lesion with FFR  $\leq 0.80$ . Enrollment in FAME 2 was stopped early because there was a highly significant difference in the primary endpoint of death, MI and urgent revascularization favoring the FFR-guided PCI arm. This was due to a significantly greater rate of urgent revascularization in the medical therapy arm (11.1% vs. 1.6%,  $P<0.001$ ); there was no difference in death or MI.

A landmark analysis suggested a higher rate of spontaneous MI in the medical therapy arm starting 1 week after randomization. Patients with angiographic disease that was not hemodynamically significant (based on FFR), and therefore not enrolled in the randomized trial but followed in a registry, had a very low event rate, which supports the role of medical therapy in this group.

Thus, clinical outcome studies indicate that measuring FFR optimizes the benefit of PCI and distinguishes stenoses responsible for ischemia from functionally insignificant ones. FFR improves clinical outcomes and saves resources compared with angiography-guided PCI. For optimal outcomes, FFR should be employed when decisions regarding the need for PCI are ambiguous based on the coronary angiogram and available noninvasive data. FFR is especially useful when noninvasive testing is absent, equivocal, or does not provide objective evidence of ischemia in the myocardial segment subtended by the targeted lesion. FFR can justify a procedure if the clinical context suggests a potential benefit. Judgment should always be used when assessing the risk:benefit ratio in clinical decision-making, however, and thus an abnormal FFR does not compel a revascularization procedure.

### Expanded Applications of FFR

In the presence of intermediate stenoses, or when there is an apparent discordance between lesion severity, location of ischemia by noninvasive testing and clinical symptoms, FFR provides valuable data for clinical decision-making. The limitations of angiography in characterizing intermediate severity stenoses are another important lesson from FAME [12]. In lesions with 50 to 70% diameter narrowing, only 35% were hemodynamically significant based on FFR. In lesions with 71 to 90% diameter stenosis, for which many operators would perform PCI, 20% were not hemodynamically significant based on FFR and did not require PCI. Therefore, FFR can be useful in guiding revascularization decisions even in more severe angiographic stenoses when noninvasive data is not available or discordant with coronary angiography.

These findings have implications for determining the optimal treatment strategy in patients with multivessel CAD. By measuring FFR and discounting non-ischemic lesions, the Functional SYNTAX Score can be calculated and angiographic three-vessel CAD can be reclassified as one- or two-vessel CAD, which could benefit from PCI and not require CABG [16].

Table II [17-23] summarizes the studies that assess revascularization in left main coronary stenosis (LMCA) based on FFR. FFR  $<0.75$  is a clinically

T2

4 Lotfi et al.

TABLE II. Using Fractional Flow Reserve to Guide Unprotected Left Main Intervention

Study	N	Defining		Follow-up		Revascularization of LM	Survival defer (%)	Survival revascularization (%)	RR CI [95% CI]
		iLM (%)	FFR cutoff	(mo)	Defer				
Bech et al. [17] <sup>a</sup>	54	40–60	0.75	29 ± 15	24	30 CABG	100	97	0.80 [0.05–12.13]
Jiménez-Navarro et al. [18] <sup>a</sup>	27	30–50	0.75	26 ± 12	20	7 CABG	100	86	7.87 [0.35–173.98]
Legutko et al. [19] <sup>a</sup>	38	30–60	0.75	24 (12–36)	20	12 CABG, 5 PCI, 1 OMT	100	89	5.526 [0.28–107.96]
Suemaru et al. [20]	15	25–75	0.75	32.5±9.7	8	7 CABG	100	100	Excluded
Lindstaedt et al. [21] <sup>a</sup>	51	40–80	0.75–0.80	29 ± 16	24	27 CABG	100	81	8.03 [0.45–141.94]
Courtis et al. [22] <sup>b</sup>	142	30–60	0.75	14 ± 11	82	54 CABG, 6 PCI	96	95	1.36 [0.28–6.53]
Hamilos et al. [23] <sup>a</sup>	213	30–70	<0.80	36 (6–99)	138	75 CABG	89.8	85.4	1.84 [0.67–5.04]
Total	540				316	224	96	90	2.28 [1.12–4.60] <sup>c</sup>

<sup>a</sup>Route of adenosine—IV.

<sup>b</sup>Route of Adenosine—IC.

<sup>c</sup>Heterogeneity  $\chi^2 = 2.85$  (df = 5),  $P = 0.723$  I-squared (variation in RR attributable to heterogeneity) = 0.0%. Test of RR = 1:  $z = 2.30$ ,  $P = 0.022$ .

iLM, intermediate left main; FFR, fractional flow reserve; IVUS, intravascular ultrasound; IC, intracoronary; IV, intravenous; MLA, minimum luminal area; MLD, minimum luminal diameter; PCI, percutaneous coronary intervention; pLM, protected left main; LAD, left anterior descending ; Lcx left circumflex; CABG, coronary artery bypass grafting; ND, not defined; NA, not applicable, RR, relative risk, CI, confidence interval.

effective tool when used as a cutoff for guiding revascularization decisions and is the preferred technique for evaluating intermediate LMCA lesions.

FFR can be used to evaluate the significance of serial stenoses to guide the strategy for determining which lesion(s) should be revascularized and which should be managed medically [24]. Observational studies have reported favorable outcomes using FFR in specific anatomic subsets, including diffuse disease [25], bifurcations [26], stent-jailed side branches [27], and nonculprit lesions in ST-segment elevation myocardial infarction [28], but none of these subsets have been the subject of randomized trials.

FFR is valid in all nonculprit vessels in non-ST-elevation ACS and valid in most nonculprit vessels in STEMI, with the caveat that STEMI with markedly elevated LVEDP and impaired global microcirculatory function may result in transiently and falsely elevated FFR. The reason is that microvascular impairment reduces the flow across the stenosis, elevating FFR. Therefore, in this setting, a low FFR indicates hemodynamic significance of the non-culprit lesion but a normal FFR is not definitive. The application of FFR in these clinical situations remains to be fully elucidated.

The potential role of “functional angioplasty” (i.e., performing PCI on lesions responsible for ischemia and treating medically those that are not), as opposed to complete anatomic revascularization (performing PCI on all lesions that appear angiographically significant) as

tested in the FAME trials, would constitute a substantial change from traditional practice. It is quite likely that in the future, functional PCI using FFR or an equivalent physiologic guide will be the measure of PCI appropriateness [10]. Instead of relying solely on angiographic criteria of severity when there is no stress test present, or the stress test/anatomy results are discordant, FFR would be the final arbiter, irrespective of lesion severity [29].

**Intravascular Ultrasound (IVUS)**

IVUS is a catheter-based imaging modality that provides high-resolution cross-sectional images of the coronary artery, enabling measurements of luminal and vessel areas [30]. Plaque morphology and constituents are identified by the amplitude and frequency of reflected ultrasound signals that correspond to normal tissue, fibrosis, calcium, and necrotic core. The axial resolution is 100 to 200  $\mu\text{m}$  and lateral resolution is 250  $\mu\text{m}$  with frequencies of 20 to 40 MHz [31].

IVUS quantification of a stenosis has fewer anatomic limitations than angiography. IVUS algorithms accurately measure minimum luminal area (MLA), a more accurate dimension than luminal diameter. The main limitation is ensuring imaging in a coaxial position. IVUS is an excellent method for determining plaque volume; however, despite numerous investigative applications, its precise role in clinical decision-making has not been defined.

**TABLE III. Studies Comparing Angiographic Versus IVUS Guidance for Percutaneous Coronary Intervention with Drug-Eluting Stents**

Study	N (IVUS/Angio)	Death HR (95% CI)	MI HR (95% CI)	Stent thrombosis HR (95% CI)	TVR HR (95% CI)
Roy et al. [35]	884/884	0.81 (0.55–1.20)	0.69 (0.36–1.32)	0.59 (0.39–0.89)	0.95 (0.68–1.32)
Park et al. [36]	145/145	0.39 (0.15–1.20)	0.83 (0.43–1.59)	3.00 (0.12–76.9)	0.80 (0.35–1.84)
Kim et al. [37]	308/112	0.21 (0.06–0.73)	NA	0.28 (0.06–1.28)	NA
Jakabcin et al. [38]	105/105	1.50 (0.15–15.4)	0.25 (0.02–3.97)	0.67 (0.15–3.00)	NA
Kim et al. [32]	487/487	0.58 (0.21–1.61)	0.32 (0.09–1.16)	0.33 (0.04–2.96)	NA
Claessen et al. [39]	631/873	0.74 (0.37–1.47)	0.18 (0.06–0.55)	0.60 (0.10–3.51)	0.91 (0.63–1.31)
Hur et al. [40]	2,765/1,816	0.49 (0.35–0.69)	0.50 (0.22–1.12)	0.72 (0.44–1.17)	0.99 (0.76–1.28)
Ahmed et al. [41]	1,893/6,280	0.49 (0.28–0.86)	1.78 (1.05–3.03)	NA	0.63 (0.26–1.53)
Park et al. [42]	619/802	1.56 (0.48–5.09)	2.77 (1.01–7.59)	0.52 (0.10–2.68)	0.95 (0.51–1.77)
Chen et al. [43]	324/304	0.55 (0.19–1.57)	0.52 (0.26–1.03)	0.18 (0.05–0.61)	0.66 (0.41–1.06)
Overall	8,161/11,808	0.59 (0.48–0.72)	0.81 (0.63–1.06)	0.58 (0.44–0.77)	0.90 (0.77–1.05)

Hazard ratios (HR) indicate improved outcomes with intravascular ultrasound (IVUS) guidance when <1, and improved outcomes with angiographic (Angio) guidance alone when HR >1. Reported outcomes include death, myocardial infarction (MI), stent thrombosis, and target vessel revascularization (TVR). Data adapted from Ref. [68], with permission from Toulouse : Société Europa édition, c2005.

IVUS can be especially useful in situations in which angiographic imaging is considered unreliable, such as the presence of ostial lesions or segments with multiple overlapping vessels. Bifurcation lesions are particularly difficult to assess by angiography because overlapping side branches often obscure the lesion. IVUS may provide an optimal assessment in these subsets.

Perhaps the most important use of IVUS is as an adjunct before and during PCI. It is especially useful in planning PCI strategy in high-risk subsets, such as left main stenosis, calcified lesions, and bifurcations [32]. It is also helpful during stent placement to assess stent sizing, expansion, and apposition. Although IVUS has not been definitively shown to impact procedural mortality or MI when routinely used during PCI, there are data suggesting that IVUS-guided stent placement reduces stent thrombosis, restenosis, and repeat revascularization [33]. A meta-analysis by Zhang et al. [34] (Table III) showed improved clinical outcomes using IVUS to direct PCI. While there was no significant reduction in MI rate, stent thrombosis, and mortality were significantly reduced in the IVUS guided group [32,35–43]. Recently, the ADAPT-DES study evaluated 1-year clinical outcomes in patients undergoing PCI with DES [44]. IVUS-guided PCI changed the interventional strategy in 74% of cases; at 1 year, there was a significant reduction in definite/probable stent thrombosis (0.52% vs. 1.04%, *P*=0.01) and MI (2.5% vs. 3.7%, *P*=0.002) but no reduction in mortality (1.0% vs. 1.4%, *P*=0.14). For LMCA stenosis, IVUS is an important procedural adjunct, both pre- and postintervention, if stenting is being considered [45].

### Optical Coherence Tomography (OCT)

OCT uses the scattering and absorption of near-infrared light. The OCT light source operates on a

wavelength range of 1,250 to 1,350 nm, providing tissue penetration of 1 to 3 mm, and a spatial resolution at the cellular level [46]. It has very high axial and lateral resolution, which provides accurate characterization of plaque morphology and composition in real-time, including thin fibrous caps, lipid pools, and fibrocalcific plaques [47]. OCT has better resolution than IVUS, but less power of penetration. OCT is better at looking at fine detail in the near field, around the lumen and stent edges, but is less valuable for imaging plaque size or determining tissue characteristics. The improved spatial resolution compared to IVUS has raised the possibility that OCT could ultimately replace IVUS. However, its limited depth of penetration mitigates its ability to visualize the external elastic lamina, especially in large or proximal vessels.

There are no prospective randomized trials of OCT for guiding PCI, but there are several single center trials that suggest the potential for improving poststent clinical decision-making [48–51]. OCT can demonstrate thrombus, unrecognized plaque rupture, stent underexpansion, significant edge dissections, and excessive plaque at the stent edges treatable with further stent expansion or the placement of additional stents. IVUS can also detect these conditions, but OCT provides improved resolution. In the multicenter CLI-OPCI trial [52], OCT identified adverse features requiring further intervention in 35% of cases. The OCT arm had a significantly lower risk of death and MI at 1 year. OCT has potential benefit as an adjunct means of evaluating the anatomy and composition of stenoses of uncertain severity or morphology, but this application needs further evaluation.

Of particular interest is its capability to determine fibrous cap thickness, potentially identifying vulnerable plaque, and perhaps predict impending rupture [53–55]. The identification of thrombus is more accurate with

6 Lotfi et al.

**TABLE IV. Studies Correlating Intravascular Ultrasound Parameters to Fractional Flow Reserve to Identify Significant Left Main**

Study	N	Defining iLM	FFR cutoff	IVUS correlation with FFR	Route of adenosine	Follow-up	Defer	Revascularization	Survival defer (%)	Survival revascularization (%)
Jasti et al. [58]	55	ND	0.75	MLA 5.9 mm <sup>2</sup> . Sensitivity 93%, specificity 95%. MLD 2.8 mm. Sensitivity 93%, specificity 98%	IC	38 mo	24	20 PCI pLM, LAD, or Lcx, 11 CABG	100	100
Kang et al. [60]	55	30–80%	0.80	MLA 4.8 mm <sup>2</sup> . Sensitivity 89%, specificity 83%	IV	Functional	25	29 PCI, 1 CABG	NA	NA

iLM, intermediate left main; FFR, fractional flow reserve; IVUS, intravascular ultrasound; IC, intracoronary; IV, intravenous; MLA, minimum luminal area; MLD, minimum luminal diameter; PCI, percutaneous coronary intervention; pLM, protected left main; LAD, left anterior descending ; Lcx, left circumflex; CABG, coronary artery bypass grafting; ND, not defined; NA, not applicable.

OCT than with IVUS. A recent study [52] identified patients with ST-elevation-MI who could be treated with thrombus aspiration alone based on an OCT finding of plaque erosion rather than fibrous cap rupture, suggesting unique medical and cost saving possibilities.

To assess the correlation between OCT luminal dimensions and FFR, Shiono et al. [56] evaluated 62 intermediate coronary lesions in 59 patients. An OCT-derived MLA = 1.91 mm<sup>2</sup> (sensitivity = 93.5%, specificity = 77.4%), MLD = 1.35 mm (sensitivity = 90.3%, specificity = 80.6%), and percent lumen area stenosis >70% (sensitivity = 96.8%, specificity = 83.9%) had the best cutoff values for a FFR <0.75. Gonzalo et al. [57] compared OCT and IVUS with FFR to determine the accuracy of OCT in identifying hemodynamically severe coronary stenoses in 61 stenoses studied in 56 patients. Although OCT and IVUS demonstrated a similar diagnostic accuracy in detecting lesions with FFR <0.80, OCT was superior in the subgroup of vessels <3 mm diameter.

To date, no prospective randomized studies have been performed to demonstrate improvement in clinical outcomes from this technology. There is no proven impact on mortality, MI, stent thrombosis, or restenosis rates. There are also no prospective randomized trials assessing the role of OCT-guided PCI. Since OCT, like IVUS, evaluates anatomic dimensions rather than functional significance, its use in assessing lesion physiology will probably be limited. As a result, this imaging modality remains investigational in terms of improving clinical outcomes associated with the performance of PCI.

**FFR Versus IVUS**

**LMCA stenosis.** Accurate quantification of the severity of LMCA stenoses can be a valuable adjunct to diagnosis when coronary angiography gives equivocal or ambiguous images. When using IVUS to determine LMCA severity, the most widely used parameter is MLA.

IVUS assessment has a relatively strong correlation with FFR in evaluating intermediate LMCA stenoses. A normal FFR can be predicted reasonably well with IVUS dimensions [58,59]. Limited variability in LMCA length, diameter, and amount of supplied myocardium explains the better correlation in LMCA than non-LMCA stenoses. However, both techniques have theoretical and practical limitations. Proximal LAD and/or LCX disease can impact FFR of LMCA stenoses. With IVUS, distal LMCA lesions can be difficult to accurately image, and often requires pullback from both the LCX and LAD.

Table IV [58,60] summarizes the studies that correlated IVUS MLA in LMCA stenoses with FFR. Jasti et al. [58] showed good correlation between FFR and IVUS, with sensitivities and specificities >0.90. In a study of 55 intermediate LMCA lesions, an MLA <5.9 mm<sup>2</sup> and an MLD <2.8 mm correlated well with FFR<0.75 [61]. In 354 intermediate left main stenoses, an MLA >6.0 mm<sup>2</sup> identified patients at low risk for adverse events with deferred revascularization [32]. A prospective application of these criteria was tested in the LITRO study [62]. LMCA revascularization was performed in 90.5% (152 of 168) of patients with an MLA <6 mm<sup>2</sup> and was deferred in 96% (179 of 186)

T4

of patients with an MLA  $>6$  mm<sup>2</sup>. In a 2-year follow-up period, cardiac death-free survival was 97.7% in the deferred group versus 94.5% in the revascularized group ( $P = \text{ns}$ ), and event-free survival was 87.3% versus 80.6%, respectively ( $P = \text{ns}$ ). At 2-year follow-up, only eight (4.4%) patients in the deferred group required subsequent LMCA revascularization, none of who had an MI.

Thus, it is safe to defer LMCA revascularization with MLA  $>6$  mm<sup>2</sup>. Additionally, the data confirms that MLA  $<6.0$  mm<sup>2</sup> is clinically significant, correlates with FFR  $<0.75$ , and may warrant intervention to improve 1-year mortality [60]. In Asian populations, with smaller normal coronary diameters, an MLA cut-off  $<4.8$  mm<sup>2</sup> correlates better with reduced FFR  $<0.8$  and  $<4.1$  mm<sup>2</sup> with FFR  $<0.75$  [36,60].

**Non-LMCA stenosis.** The primary limitation of IVUS MLA in predicting hemodynamic significance in non-LMCA lesions is that the functional effects of a lesion are dependent on additional factors besides dimension. These include lesion location in the coronary tree, lesion length, eccentricity, entrance and exit angles, shear forces, reference vessel dimensions, and the amount of viable myocardium subtended by the lesion [25]. Therefore, in non-LMCA lesions there is only moderate correlation between anatomic dimensions by IVUS and ischemia by physiological assessment. The IVUS and FFR correlation is best in demonstrating nonsignificant lesions [59]; their correlation in demonstrating significant stenoses is weaker. Part of the reason for this deficiency is that attempting to determine a critical MLA without considering the reference vessel MLA leads to inaccuracy. An MLA = 3.0 mm<sup>2</sup> in a proximal versus distal arterial segment has entirely different effects on flow and subsequent clinical implications.

In non-LMCA stenosis, IVUS MLA  $<4.0$  mm<sup>2</sup> correlates with ischemia on single-photon emission computed tomography and also correlates moderately well with an FFR  $<0.75$  (sensitivity and specificity 92% and 56%, respectively). Importantly, low event rates are observed in intermediate lesions when intervention is deferred with an IVUS MLA  $\geq 4$  mm<sup>2</sup> [63–65].

In the largest study to date, IVUS was compared with FFR in 544 lesions [66]. The optimal cut-off value for predicting an FFR  $\leq 0.80$  was an MLA = 2.9 mm<sup>2</sup> by IVUS, but the overall accuracy was only 66%. Moreover, of the 240 lesions that had an MLA  $<2.9$  mm<sup>2</sup>, only 47% were hemodynamically significant by FFR. Similarly concerning, 19% of lesions with an MLA  $>2.9$  mm<sup>2</sup> had an FFR  $<0.80$ , limiting the utility of IVUS for lesion assessment.

Kang et al. [60] evaluated 236 angiographically intermediate coronary lesions in which both IVUS and

FFR measurements were performed. An IVUS MLA  $\leq 2.4$  mm<sup>2</sup> had the maximum accuracy for predicting FFR  $<0.80$ . However, the overall diagnostic accuracy was 68% with a confidence interval ranging from 1.8 to 2.6 mm<sup>2</sup>.

FIRST was a multicenter prospective registry of patients who underwent elective coronary angiography and had intermediate coronary stenoses (40–80%) [67]. An IVUS-measured MLA  $<3.07$  mm<sup>2</sup> had the best sensitivity and specificity (64% and 64.9%, respectively) for correlating with FFR  $<0.80$ .

Thus, FFR is better validated than IVUS as a physiologic assessment and should be considered the standard for assessing the hemodynamic significance of intermediate non-LMCA lesions. An MLA  $\geq 4.0$  mm<sup>2</sup> has reasonable accuracy in identifying non-significant lesions for which PCI can be safely deferred. However, an MLA  $<4.0$  mm<sup>2</sup> does not accurately predict a hemodynamically significant lesion and should not be used in the absence of supporting functional data to recommend revascularization [25]. An MLA  $<3.0$  mm<sup>2</sup> is most likely a significant stenosis, but due to its only modest sensitivity and specificity, physiologic testing is desirable before proceeding with revascularization.

## Recommendations

The writing group recommends that the following conclusions be adopted in clinical practice and in future guidelines and appropriateness documents.

### Fractional flow reserve (FFR).

**Definitely Beneficial.** In SIHD, when noninvasive stress imaging is contraindicated, discordant, nondiagnostic, or unavailable, FFR should be used to assess the functional significance of intermediate coronary stenoses (50–70%) and more severe stenoses ( $<90\%$ ).

In patients with multivessel coronary disease, PCI guided by FFR measurement improves outcomes and saves resources when compared to PCI guided by angiography alone.

In patients with three-vessel coronary disease, measuring FFR could allow reclassification of number of vessels diseased and/or SYNTAX score, thereby guiding decisions regarding revascularization by CABG or PCI.

In SIHD, PCI of lesions with FFR  $<0.80$  improves symptom control and decreases the need for hospitalization requiring urgent revascularization when compared with medical therapy alone.

In SIHD, medical therapy is indicated for an angiographically intermediate stenosis (LMCA or non-LMCA) of unclear clinical significance when FFR  $>0.80$ .

**No Proven Benefit.** FFR measurement of the culprit vessel in a patient with an acute ST segment elevation

myocardial infarction or any unstable acute coronary syndrome presentation should not be performed.

#### **Intravascular ultrasound (IVUS).**

**Definitely Beneficial.** IVUS is an accurate method for determining optimal stent deployment (complete stent expansion and apposition and lack of edge dissection or other complications after implantation), and the size of the vessel undergoing stent implantation.

**Probably Beneficial.** IVUS can be used to appraise the significance of LMCA stenosis and, employing a cutoff MLA = 6 mm<sup>2</sup>, assess whether revascularization is warranted.

**Possibly Beneficial.** IVUS can be useful for the assessment of plaque morphology.

**No Proven Value/Should be Discouraged.** IVUS measurements for determination of non-LMCA lesion severity should not be relied upon, in the absence of additional functional evidence, for recommending revascularization.

#### **Optical Coherence Tomography (OCT).**

**Probably Beneficial.** Determination of optimal stent deployment (sizing, apposition, and lack of edge dissection), with improved resolution compared with IVUS.

**Possibly Beneficial.** OCT can be useful for the assessment of plaque morphology.

**No Proven Value/Should be Discouraged.** OCT should not be performed to determine stenosis functional significance.

The writing group concurs with current guidelines that these modalities are not indicated when non-invasive imaging and angiographic data are concordant or when the result of the additional procedure will not alter the planned treatment strategy or optimization of stent implantation.

## REFERENCES

1. Topol EJ, Nissen SE. Our preoccupation with coronary luminology. The dissociation between clinical and angiographic findings in ischemic heart disease. *Circulation* 1995;92:2333–2342.
2. McDaniel MC, Eshthardi P, Sawaya FJ, Douglas JS Jr, Samady H. Contemporary clinical applications of coronary intravascular ultrasound. *JACC Cardiovasc Interv* 2011;4:1155–1167.
3. Zir LM, Miller SW, Dinsmore RE, Gilbert JP, Harthorne JW. Interobserver variability in coronary angiography. *Circulation* 1976;53:627–632.
4. White CW, Wright CB, Doty DB, Hiratzka LF, Eastham CL, Harrison DG, Marcus ML. Does visual interpretation of the coronary arteriogram predict the physiologic importance of a coronary stenosis? *N Engl J Med* 1984;310:819–824.
5. Yong AS, Ng AC, Brieger D, Lowe HC, Ng MK, Kritharides L. Three-dimensional and two-dimensional quantitative coronary angiography, and their prediction of reduced fractional flow reserve. *Eur Heart J* 2011;32:345–353.
6. Christou MA, Siontis GC, Katritsis DG, Ioannidis JP. Meta-analysis of fractional flow reserve versus quantitative coronary angiography and noninvasive imaging for evaluation of myocardial ischemia. *Am J Cardiol* 2007;99:450–456.
7. Dattilo PB, Prasad A, Honeycutt E, Wang TY, Messenger JC. Contemporary patterns of fractional flow reserve and intravascular ultrasound use among patients undergoing percutaneous coronary intervention in the United States: Insights from the National Cardiovascular Data Registry. *J Am Coll Cardiol* 2012;60:2337–2339.
8. Levine GN, Bates ER, Blankenship JC, Bailey SR, Bittl JA, et al. 2011 ACCF/AHA/SCAI Guideline for Percutaneous Coronary Intervention: A report of the American College of Cardiology Foundation/American Heart Association Task Force on Practice Guidelines and the Society for Cardiovascular Angiography and Interventions. *Circulation* 2011;124:e574–e651.
9. Pijls NH, De Bruyne B, Peels K, Van Der Voort PH, Bonnier HJ, Bartunek JKJJ, Koolen JJ. Measurement of fractional flow reserve to assess the functional severity of coronary-artery stenoses. *N Engl J Med* 1996;334:1703–1708.
10. Melikian N, De Bondt P, Tonino P, De Winter O, Wyffels Bartunek J, Heyndrickx GR, Fearon WF, Pijls NHJ, Wijns W, De Bruyne B. Fractional flow reserve research and myocardial perfusion imaging in patients with angiographic multivessel coronary artery disease. *J Am Coll Cardiol Interv* 2010;3:307–314.
11. Pijls NH, van Schaardenburgh P, Manoharan G, Boersma E, Bech JW, et al. Percutaneous coronary intervention of functionally nonsignificant stenosis: 5-year follow-up of the DEFER Study. *J Am Coll Cardiol* 2007;49:2105–2111.
12. Tonino PA, De Bruyne B, Pijls NH, Siebert U, Ikeno F, et al. Fractional flow reserve versus angiography for guiding percutaneous coronary intervention. *N Engl J Med* 2009;360:213–224.
13. Fearon WF, Bornschein B, Tonino PA, Gothe RM, Bruyne BD, Pijls NH, Siebert U. Economic evaluation of fractional flow reserve-guided percutaneous coronary intervention in patients with multivessel disease. *Circulation* 2010;122:2545–2550.
14. De Bruyne B, Pijls NH, Kalesan B, Barbato E, Tonino PA, et al. Fractional flow reserve-guided PCI versus medical therapy in stable coronary disease. *N Engl J Med* 2012;367:991–1001.
15. Boden WE, O'Rourke RA, Teo KK, Hartigan PM, Maron DJ, et al. Optimal medical therapy with or without PCI for stable coronary disease. *N Engl J Med* 2007;356:1503–1516.
16. Nam CW, Mangiacapra F, Entjes R, Chung IS, Sels JW, Tonino PA, De Bruyne B, Pijls NH, Fearon WF; FAME Study Investigators. Functional SYNTAX Score for risk assessment in multivessel coronary artery disease. *J Am Coll Cardiol* 2011;58:1211–1218.
17. Bech GJ, Droste H, Pijls NH, De Bruyne B, Bonnier JJ, Michels HR, Peels KH, Koolen JJ. Value of fractional flow reserve in making decisions about bypass surgery for equivocal left main coronary artery disease. *Heart* 2001;86:547–552.
18. Jimenez-Navarro M, Hernandez-Garcia JM, Alonso-Briaies JH, Kuhlmoegen B, Gomez-Doblas JJ, Garcia-Pinilla JM, Lopez-Salguero R, Galvan Ede T. Should we treat patients with moderately severe stenosis of the left main coronary artery and negative FFR results? *J Invasive Cardiol* 2004;16:398–400.
19. Legutko J, Dudek D, Rzeszutko L, Wizimirski M, Dubiel JS. Fractional flow reserve assessment to determine the indications for myocardial revascularisation in patients with borderline stenosis of the left main coronary artery. *Kardiologia Pol* 2005;63:499–506; discussion 507–508.
20. Suemaru S, Iwasaki K, Yamamoto K, Kusachi S, Hina K, et al. Coronary pressure measurement to determine treatment strategy for equivocal left main coronary artery lesions. *Heart Vessels* 2005;20:271–277.
21. Lindstaedt M, Yazar A, Germing A, Fritz MK, Holland-Letz T, Mugge A, Bojara W. Clinical outcome in patients with



- intermediate or equivocal left main coronary artery disease after deferral of surgical revascularization on the basis of fractional flow reserve measurements. *Am Heart J* 2006;152:156 e1-e9.
22. Courtis J, Rodes-Cabau J, Larose E, Potvin JM, Dery JP, et al. Usefulness of coronary fractional flow reserve measurements in guiding clinical decisions in intermediate or equivocal left main coronary stenoses. *Am J Cardiol* 2009;103:943-949.
  23. Hamilos M, Muller O, Cuisset T, Ntalianis A, Chlouverakis G, et al. Long-term clinical outcome after fractional flow reserve-guided treatment in patients with angiographically equivocal left main coronary artery stenosis. *Circulation* 2009;120:1505-1512.
  24. Kim HL, Koo BK, Nam CW, et al. Clinical and physiological outcomes of fractional flow reserve-guided percutaneous coronary intervention in patients with serial stenoses within one coronary artery. *JACC Cardiovasc Interv* 2012;5:1013-1018.
  25. Pijls NH, Sels JW. Functional measurement of coronary stenosis. *J Am Coll Cardiol* 2012;59:1045-1057.
  26. Koo BK, Park KW, Kang HJ, Cho YS, Chung WY, et al. Physiological evaluation of the provisional side-branch intervention strategy for bifurcation lesions using fractional flow reserve. *Eur Heart J* 2008;29:726-732.
  27. Koo BK, Kang HJ, Youn TJ, Chae IH, Choi DJ, et al. Physiologic assessment of jailed side branch lesions using fractional flow reserve. *J Am Coll Cardiol* 2005;46:633-637.
  28. Ntalianis A, Sels JW, Davidavicius G, Tanaka N, Muller O, et al. Fractional flow reserve for the assessment of nonculprit coronary artery stenoses in patients with acute myocardial infarction. *JACC Cardiovasc Interv* 2010;3:1274-1481.
  29. Park SJ, Ahn JM, Kang SJ. Paradigm shift to functional angioplasty: New insights for fractional flow reserve- and intravascular ultrasound-guided percutaneous coronary intervention. *Circulation* 2011;124:951-957.
  30. Klein LW, McPherson D. The diagnostic potential of intravascular ultrasound in the coronary arteries. *Cardiovasc Rev Rep* 1990;11:31-36.
  31. Nissen SE, Yock P. Intravascular ultrasound: novel pathophysiological insights and current clinical applications. *Circulation* 2001;103:604-616.
  32. Kim JS, Hong MK, Ko YG, Choi D, Yoon JH, et al. Impact of intravascular ultrasound guidance on long-term clinical outcomes in patients treated with drug-eluting stent for bifurcation lesions: Data from a Korean multicenter bifurcation registry. *Am Heart J* 2011;161:180-187.
  33. Parise H, Maehara A, Stone GW, Leon MB, Mintz GS. Meta-analysis of randomized studies comparing intravascular ultrasound versus angiographic guidance of percutaneous coronary intervention in pre-drug-eluting stent era. *Am J Cardiol* 2011;107:374-382.
  34. Zhang Y, Farooq V, Garcia-Garcia HM, Bourantas CV, Tian N, Dong S, Li M, Yang S, Serruys PW, Chen SL. Comparison of intravascular ultrasound versus angiography-guided drug-eluting stent implantation: A meta-analysis of one randomised trial and ten observational studies involving 19,619 patients. *EuroIntervention* 2012;8:855-865.
  35. Roy P, Steinberg DH, Sushinsky SJ, Okabe T, Pinto Slottow TL, et al. The potential clinical utility of intravascular ultrasound guidance in patients undergoing percutaneous coronary intervention with drug-eluting stents. *Eur Heart J* 2008;29:1851-1857.
  36. Park SJ, Kim YH, Park DW, Lee SW, Kim WJ, et al. Impact of intravascular ultrasound guidance on long-term mortality in stenting for unprotected left main coronary artery stenosis. *Circ Cardiovasc Interv* 2009;2:167-177.
  37. Kim SH, Kim YH, Kang SJ, Park DW, Lee SW, et al. Long-term outcomes of intravascular ultrasound-guided stenting in coronary bifurcation lesions. *Am J Cardiol* 2010;106:612-618.
  38. Jakabcin J, Spacek R, Bystron M, Kvasnak M, Jager J, Veselka J, Kala P, Cervinka P. Long-term health outcome and mortality evaluation after invasive coronary treatment using drug eluting stents with or without the IVUS guidance. Randomized control trial. HOME DES IVUS. *Catheter Cardiovasc Interv* 2010;75:578-583.
  39. Claessen BE, Mehran R, Mintz GS, Weisz G, Leon MB, et al. Impact of intravascular ultrasound imaging on early and late clinical outcomes following percutaneous coronary intervention with drug-eluting stents. *JACC Cardiovasc Interv* 2011;4:974-981.
  40. Hur SH, Kang SJ, Kim YH, Ahn JM, Park DW, Lee SW, Yun SC, Lee CW, Park SW, Park SJ. Impact of intravascular ultrasound-guided percutaneous coronary intervention on long-term clinical outcomes in a real world population. *Catheter Cardiovasc Interv* 2013;81:407-416.
  41. Ahmed K, Jeong MH, Chakraborty R, Ahn Y, Sim DS, et al. Role of intravascular ultrasound in patients with acute myocardial infarction undergoing percutaneous coronary intervention. *Am J Cardiol* 2011;108:8-14.
  42. Park KW, Kang SH, Yang HM, Lee HY, Kang HJ, Cho YS, Youn TJ, Koo BK, Chae IH, Kim HS. Impact of intravascular ultrasound guidance in routine percutaneous coronary intervention for conventional lesions: data from the EXCELLENT trial. *Int J Cardiol* 2012;167:721-726.
  43. Chen SL YF, Zhang JJ, Kan J, Tian NL, Liu ZZ, Lin S, Lin L, Han YL, Santoso T, Zhou YJ, Jiang TM, Wen SY. Intravascular ultrasound-guided systematic two-stent techniques for coronary bifurcation lesions reduced late stent thrombosis and ST-elevation myocardial infarction. *Circ Cardiovasc Interv*, in press.
  44. Witzenbichler B. Use of IVUS reduces stent thrombosis: Results from the prospective, multicenter ADAPT-DES study. *J Am Coll Cardiol* 2012;60:B6.
  45. Puri R, Kapadia SR, Nicholls SJ, Harvey JE, Kataoka Y, Tuzcu EM. Optimizing outcomes during left main percutaneous coronary intervention with intravascular ultrasound and fractional flow reserve: The current state of evidence. *JACC Cardiovasc Interv* 2012;5:697-707.
  46. Bezerra HG, Costa MA, Guagliumi G, Rollins AM, Simon DI. Intracoronary optical coherence tomography: a comprehensive review clinical and research applications. *JACC Cardiovasc Interv* 2009;2:1035-1046.
  47. Yabushita H, Bouma BE, Houser SL, Aretz HT, Jang IK, et al. Characterization of human atherosclerosis by optical coherence tomography. *Circulation* 2002;106:1640-1645.
  48. Diaz-Sandoval LJ, Bouma BE, Tearney GJ, Jang IK. Optical coherence tomography as a tool for percutaneous coronary interventions. *Catheter Cardiovasc Interv* 2005;65:492-496.
  49. Imola F, Mallus MT, Ramazzotti V, Manzoli A, Pappalardo A, Di Giorgio A, Albertucci M, Prati F. Safety and feasibility of frequency domain optical coherence tomography to guide decision making in percutaneous coronary intervention. *EuroIntervention* 2010;6:575-581.
  50. Viceconte N, Chan PH, Barrero EA, Ghilencea L, Lindsay A, Foin N, Di Mario C. Frequency domain optical coherence tomography for guidance of coronary stenting. *Int J Cardiol* 2013;166:722-728.
  51. Stefano GT, Bezerra HG, Mehanna E, Yamamoto H, Fujino Y, Wang W, Attizzani G, Chamie D, Simon DI, Costa MA. Unrestricted utilization of frequency domain optical coherence

Catheterization and Cardiovascular Interventions DOI 10.1002/ccd.

Published on behalf of The Society for Cardiovascular Angiography and Interventions (SCAI).

## 10 Lotfi et al.

- tomography in coronary interventions. *Int J Cardiovasc Imaging* 2013;29:741–752.
52. Prati F, Di Vito L, Biondi-Zoccai G, Occhipinti M, La Manna A, et al. Angiography alone versus angiography plus optical coherence tomography to guide decision-making during percutaneous coronary intervention: the Centro per la Lotta contro l'Infarto-Optimisation of Percutaneous Coronary Intervention (CLI-OPCI) study. *EuroIntervention* 2012;8:823–829.
  53. Jang IK, Tearney GJ, MacNeill B, Takano M, Moselewski F, et al. In vivo characterization of coronary atherosclerotic plaque by use of optical coherence tomography. *Circulation* 2005;111:1551–1555.
  54. Kubo T, Imanishi T, Takarada S, Kuroi A, Ueno S, et al. Assessment of culprit lesion morphology in acute myocardial infarction: ability of optical coherence tomography compared with intravascular ultrasound and coronary angiography. *J Am Coll Cardiol* 2007;50:933–939.
  55. Kato K, Yonetsu T, Kim SJ, Xing L, Lee H, et al. Nonculprit plaques in patients with acute coronary syndromes have more vulnerable features compared with those with non-acute coronary syndromes: A 3-vessel optical coherence tomography study. *Circ Cardiovasc Imaging* 2012;5:433–440.
  56. Shiono Y, Kitabata H, Kubo T, Masuno T, Ohta S, et al. Optical coherence tomography-derived anatomical criteria for functionally significant coronary stenosis assessed by fractional flow reserve. *Circ J* 2012;76:2218–2225.
  57. Gonzalo N, Escaned J, Alfonso F, Nolte C, Rodriguez V, et al. Morphometric assessment of coronary stenosis relevance with optical coherence tomography: A comparison with fractional flow reserve and intravascular ultrasound. *J Am Coll Cardiol* 2012;59:1080–1089.
  58. Jasti V, Ivan E, Yalamanchili V, Wongpraparut N, Leesar MA. Correlations between fractional flow reserve and intravascular ultrasound in patients with an ambiguous left main coronary artery stenosis. *Circulation* 2004;110:2831–2836.
  59. Takayama T, Hodgson JM. Prediction of the physiologic severity of coronary lesions using 3D IVUS: Validation by direct coronary pressure measurements. *Catheter Cardiovasc Interv* 2001;53:48–55.
  60. Kang SJ, Lee JY, Ahn JM, Song HG, Kim WJ, et al. Intravascular ultrasound-derived predictors for fractional flow reserve in intermediate left main disease. *JACC Cardiovasc Interv* 2011;4:1168–1174.
  61. Leesar MA, Masden R, Jasti V. Physiological and intravascular ultrasound assessment of an ambiguous left main coronary artery stenosis. *Catheter Cardiovasc Interv* 2004;62:349–357.
  62. de la Torre Hernandez JM, Hernandez Hernandez F, Alfonso F, Rumoroso JR, Lopez-Palop R, et al. Prospective application of pre-defined intravascular ultrasound criteria for assessment of intermediate left main coronary artery lesions results from the multicenter LITRO study. *J Am Coll Cardiol* 2011;58:351–358.
  63. Abizaid A, Mintz GS, Pichard AD, Kent KM, Satler LF, Walsh CL, Popma JJ, Leon MB. Clinical, intravascular ultrasound, and quantitative angiographic determinants of the coronary flow reserve before and after percutaneous transluminal coronary angioplasty. *Am J Cardiol* 1998;82:423–428.
  64. Nishioka T, Amanullah AM, Luo H, Berglund H, Kim CJ, et al. Clinical validation of intravascular ultrasound imaging for assessment of coronary stenosis severity: Comparison with stress myocardial perfusion imaging. *J Am Coll Cardiol* 1999;33:1870–1878.
  65. Abizaid AS, Mintz GS, Mehran R, Abizaid A, Lansky AJ, et al. Long-term follow-up after percutaneous transluminal coronary angioplasty was not performed based on intravascular ultrasound findings: importance of lumen dimensions. *Circulation* 1999;100:256–261.
  66. Stone G. VERDICT/FIRST: Prospective, Multicenter Study Examining the Correlation between IVUS and FFR Parameters in Intermediate Lesions. 2012, in press.
  67. Waksman R, Legutko J, Singh J, Orlando Q, Marso S, et al. FIRST: Fractional Flow Reserve and Intravascular Ultrasound Relationship Study. *J Am Coll Cardiol* 2013;61:917–923.